

ABDOMINAL WOUND

Abdominal Wound – Fournier Abscess

Female

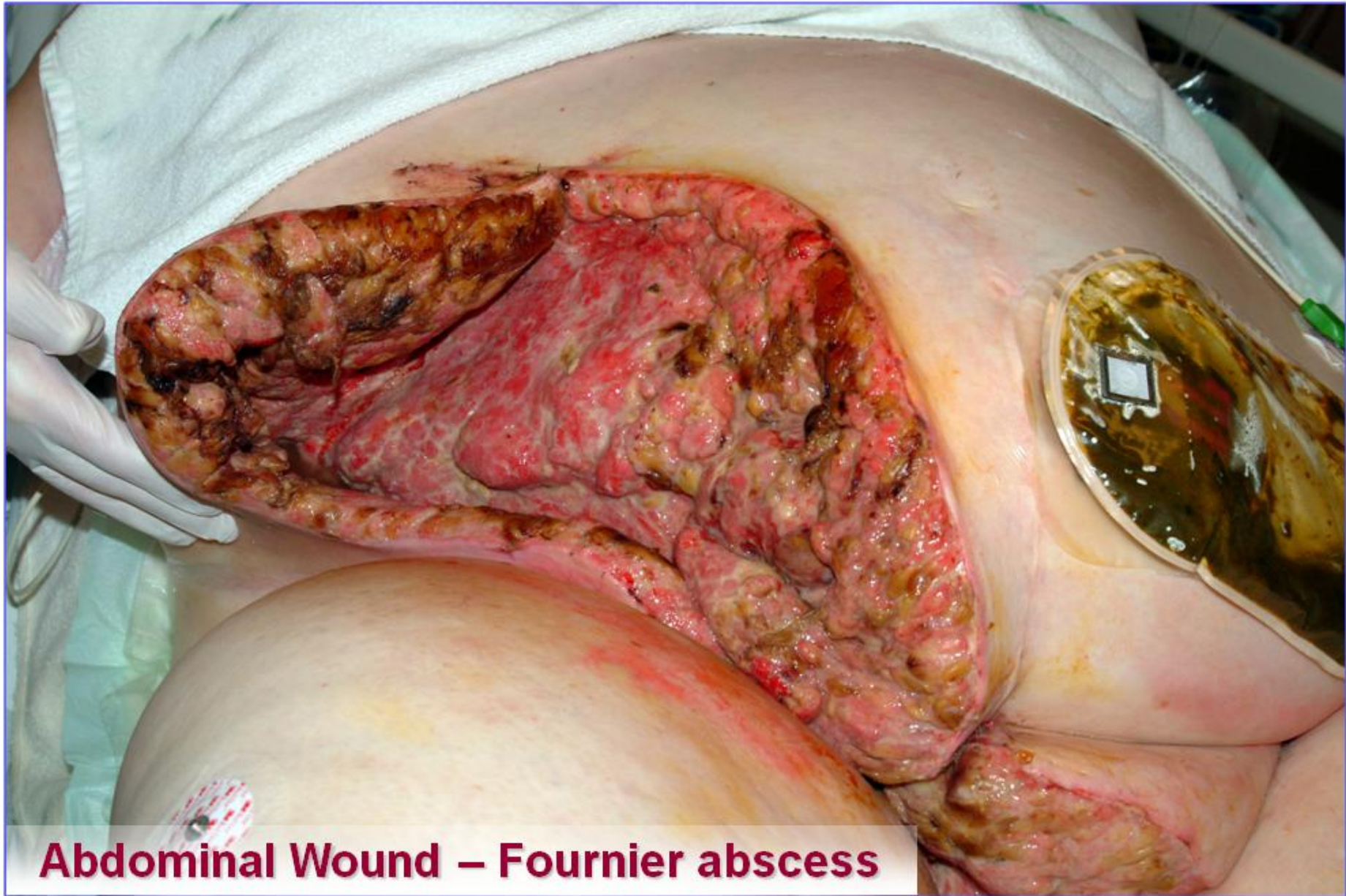
Age: 71 Years

Start Q.Light[®]: 04/09/2006

Full Closure: 13/11/2006

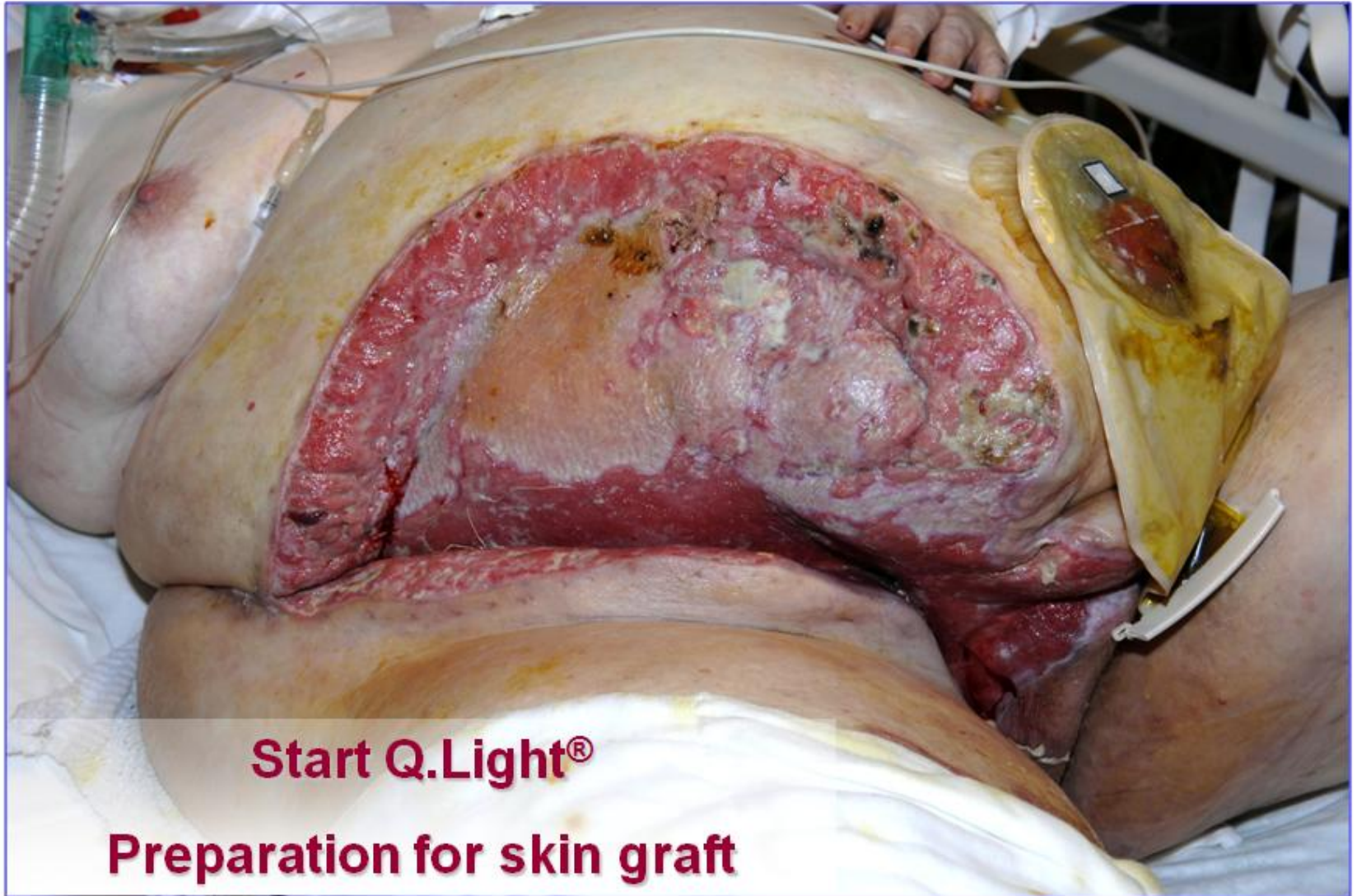Total Treatment Time: 2 months

Treatment: 12 minutes daily

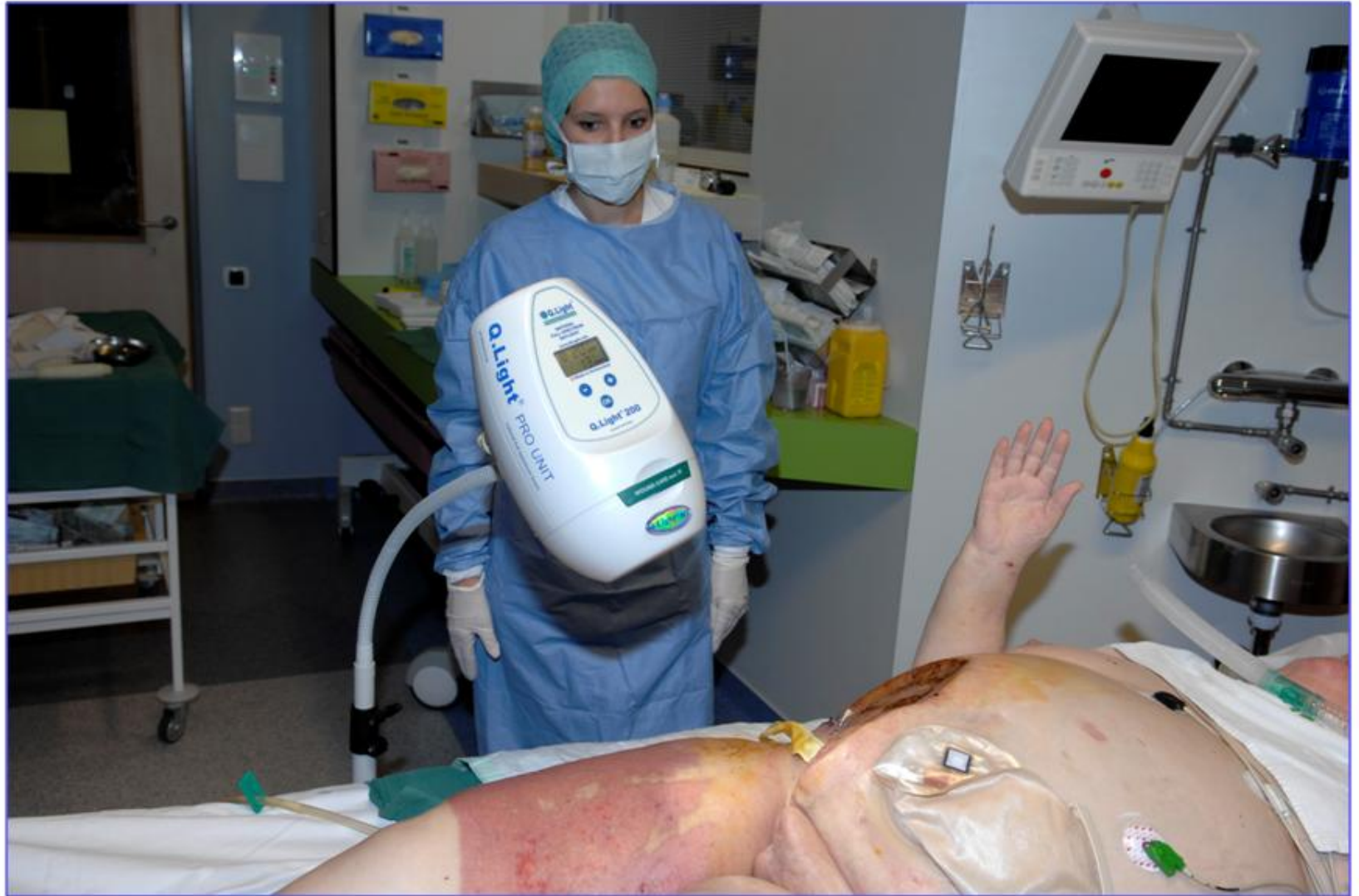

Abdominal Wound – Fournier abscess

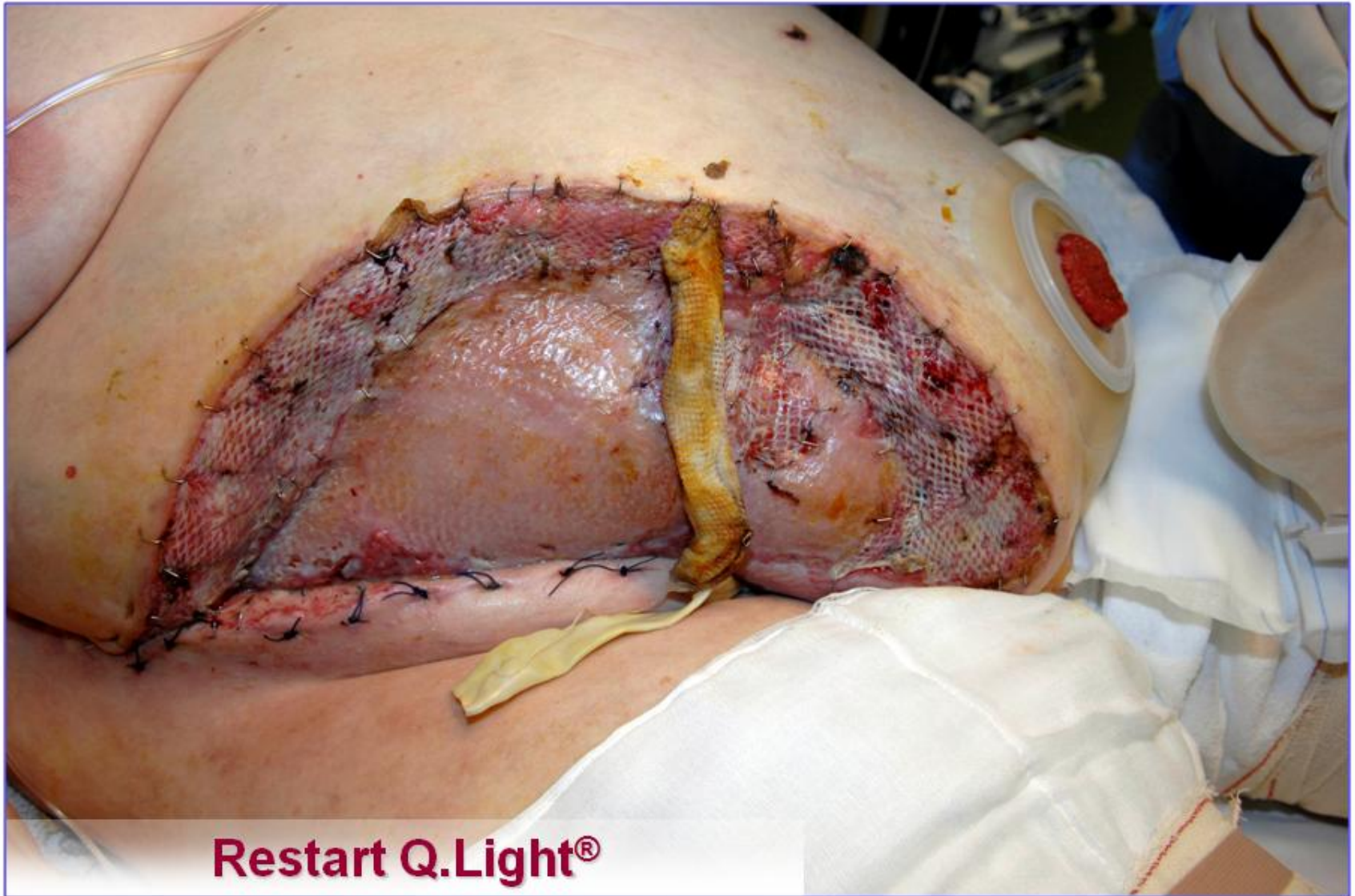
Skin Defects after Mesh Grafts



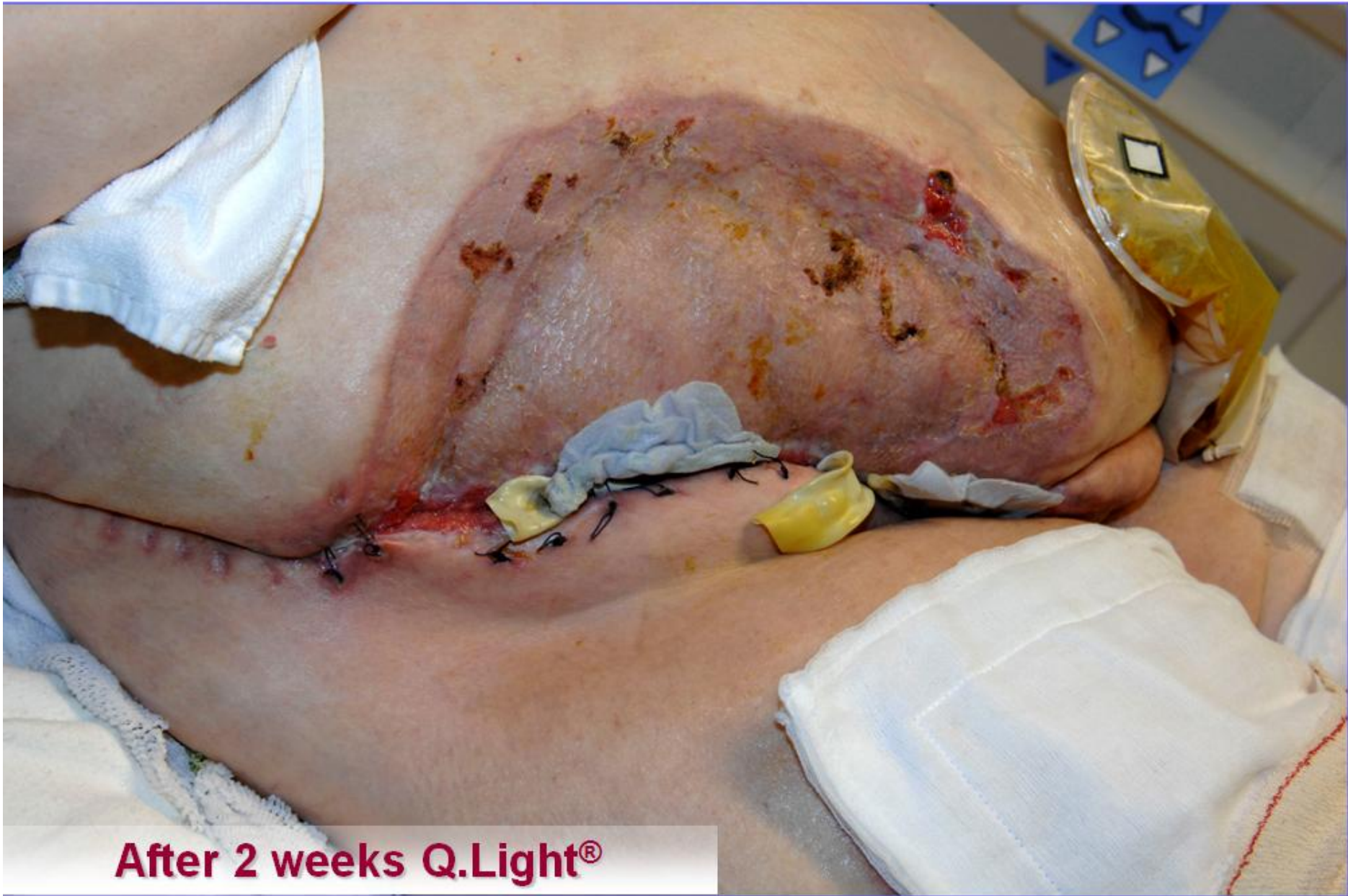Q.LIGHT®



Second mesh graft procedure

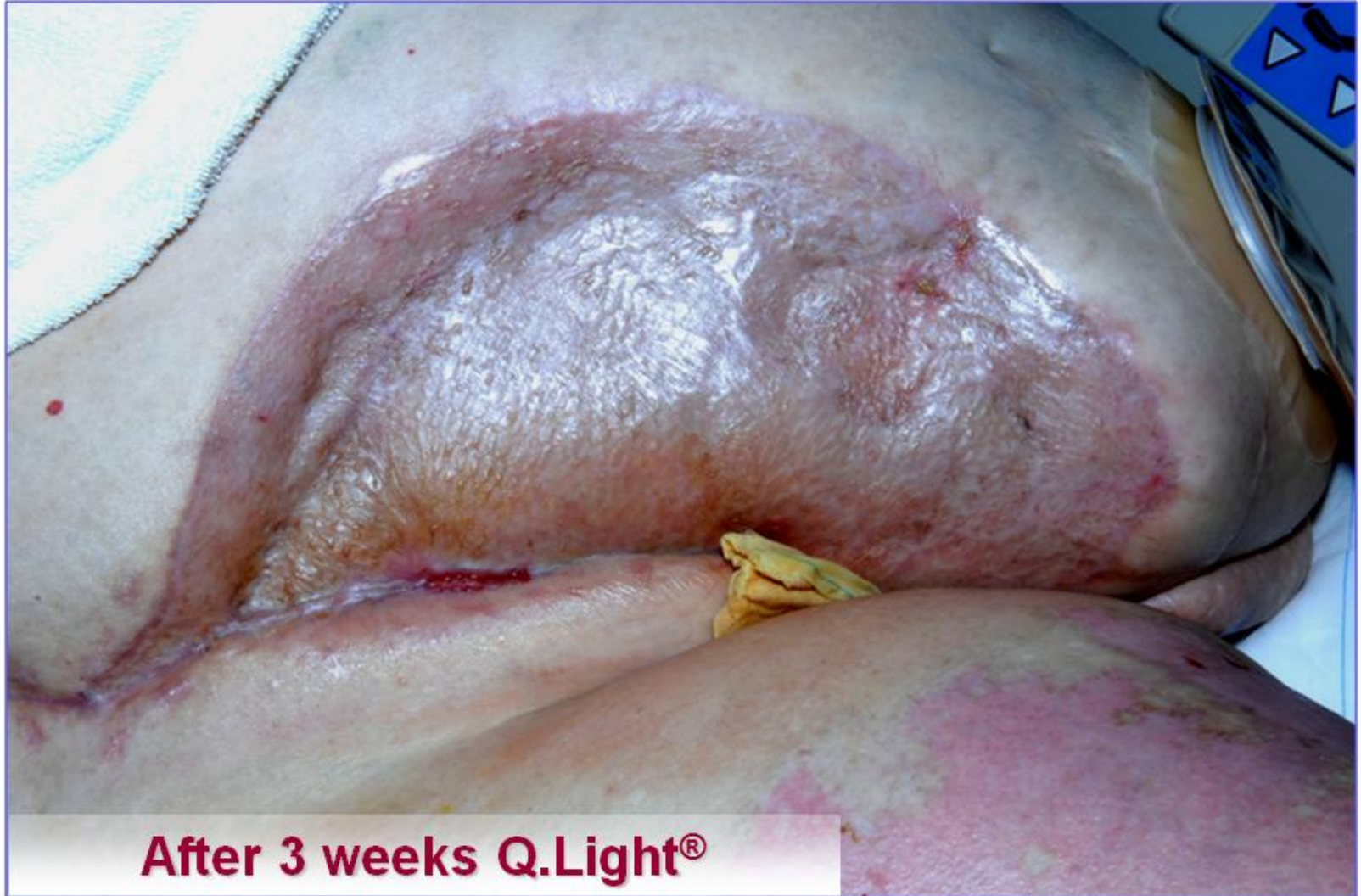

Restart Q.Light®



After 2 weeks Q.Light®

Q.LIGHT®



Q.LIGHT®

